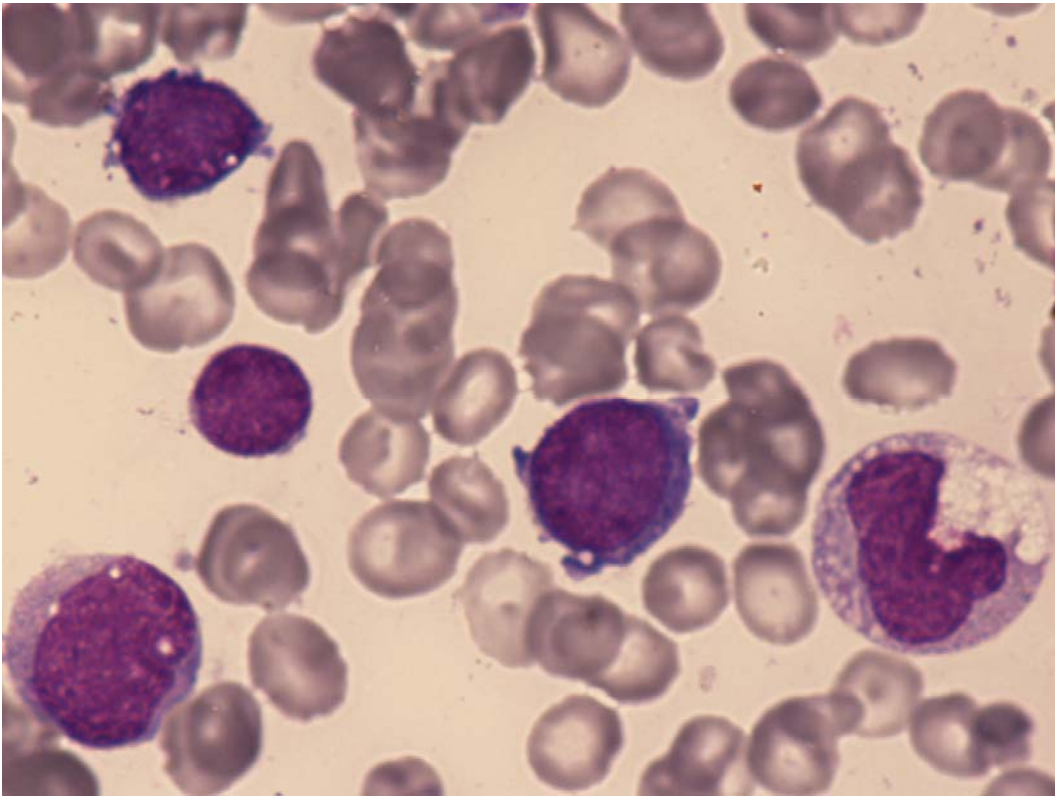
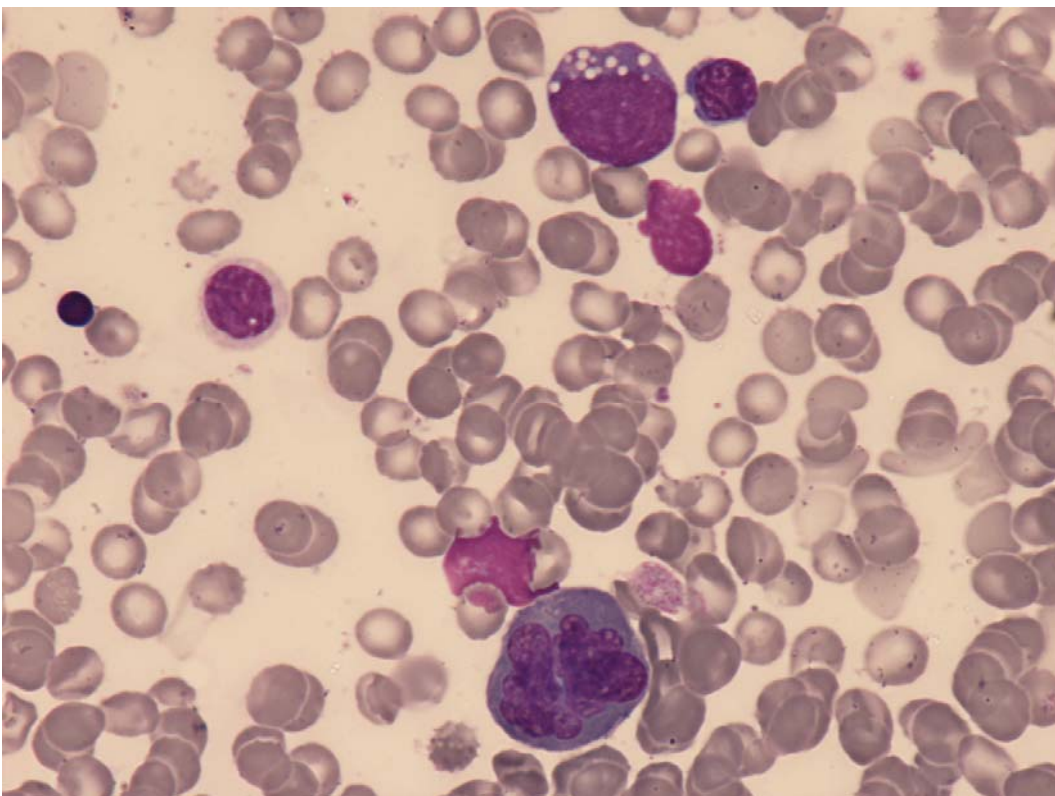


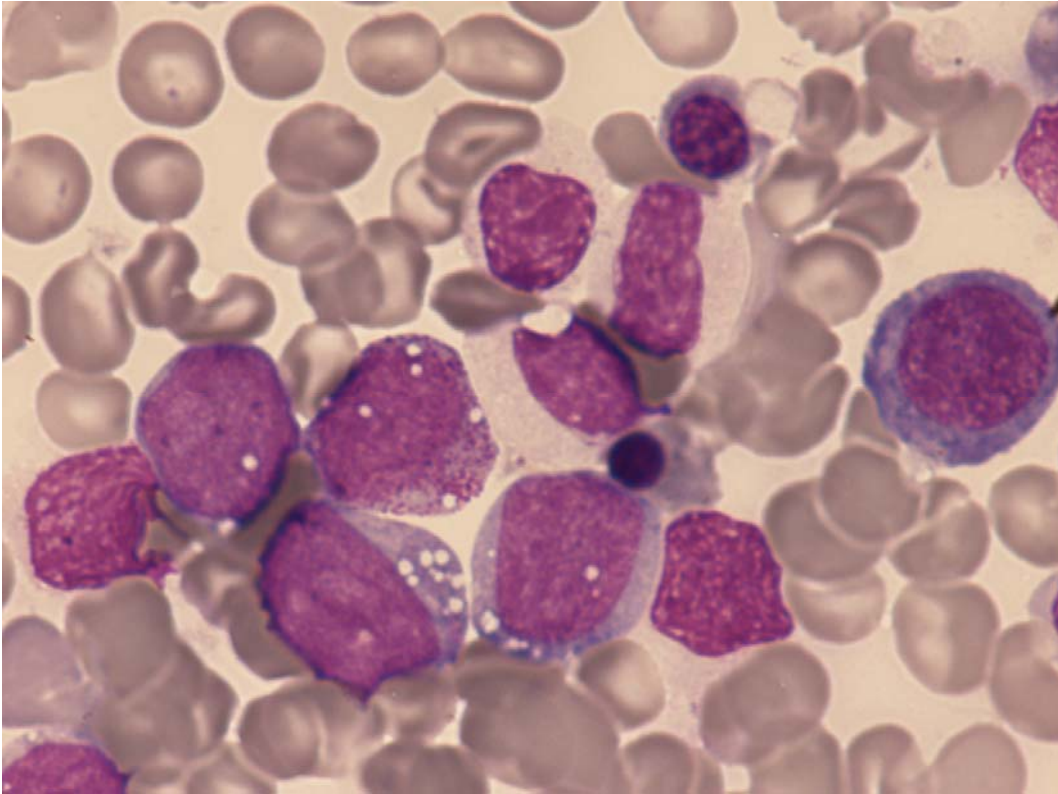
## AML & MDS THERAPY-RELATED



**Fig 1:** AML. Dysgranulopoiesis (hypogranular, vacuoles and abnormal nuclear lobation); monocytic and erythroid blasts.



**Fig 2:** AML. Dyserythropoiesis (nuclear irregularity); myeloid blast.



**Fig 3:** AML. Dysgranulopoiesis (hypogranular and hyposegmentation); monocytic blasts.