

MYXED PHENOTYPE ACUTE LEUKAEMIA, T/MYELOID

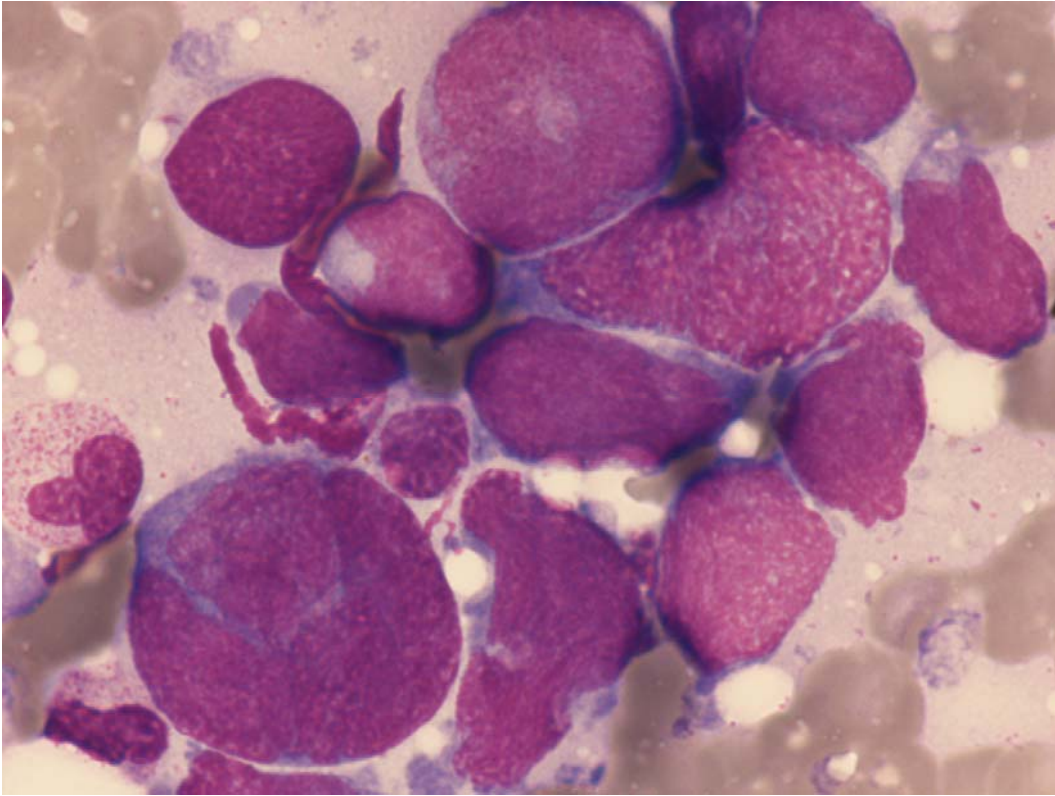


Fig 1: Bilineal acute leukaemia (myeloid and lymphoid T): blasts morphologically resembling ALL, and one with azurophilic granulation.

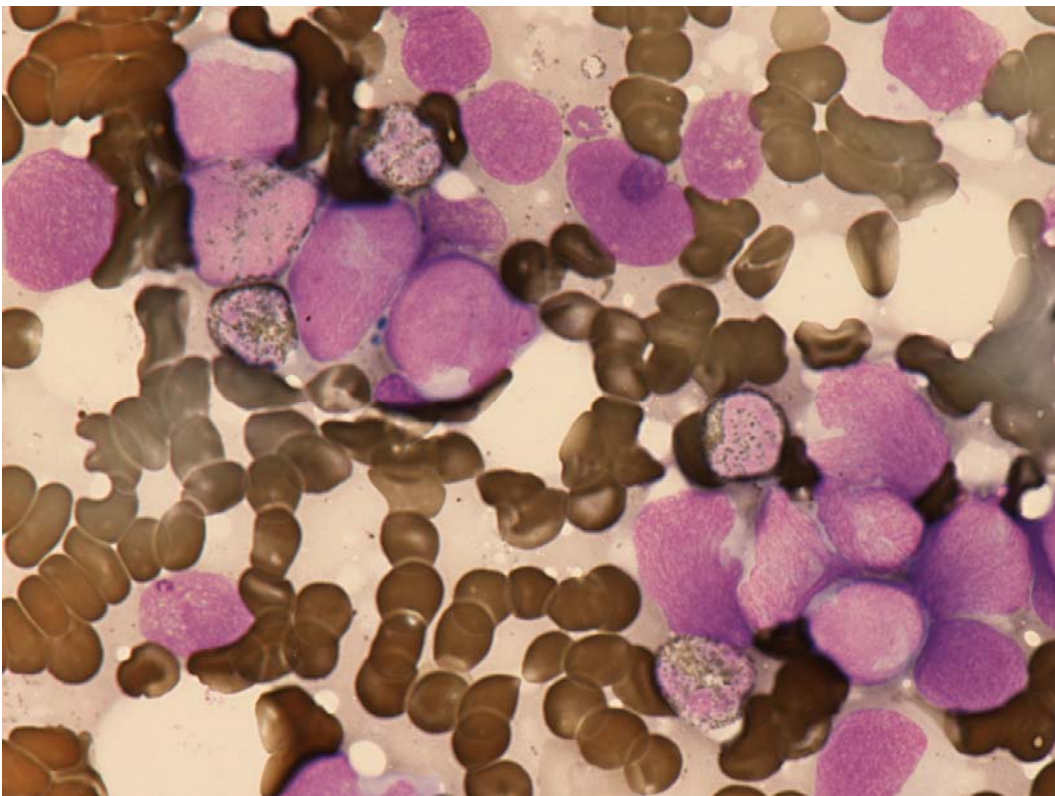


Fig 2: Bilineal acute leukaemia (myeloid and lymphoid T): Only one blast is MPO positive.

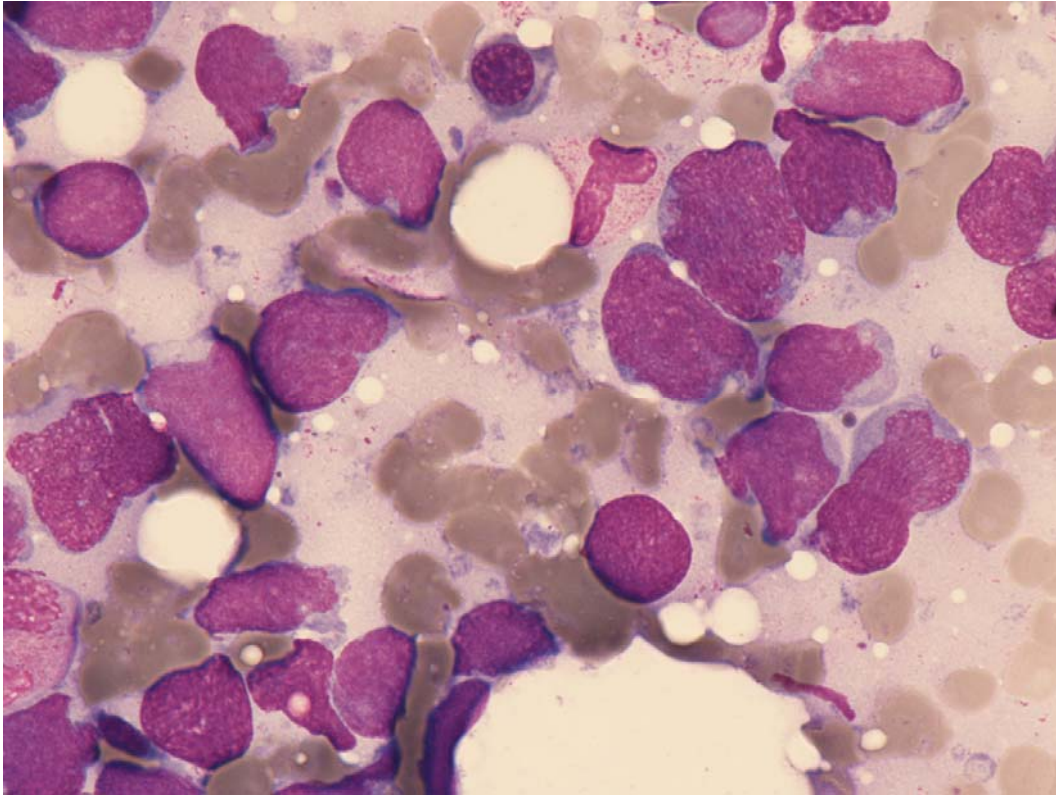


Fig 3: Bilineal acute leukaemia (myeloid and lymphoid T): blasts morphologically resembling ALL.