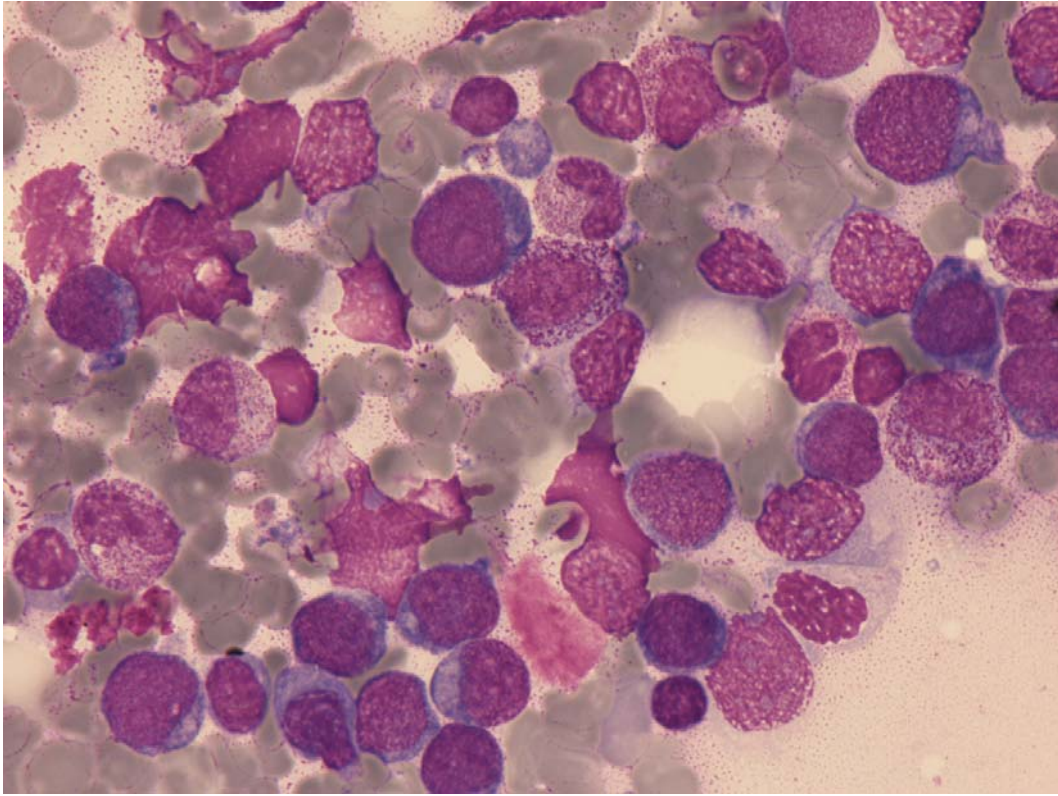
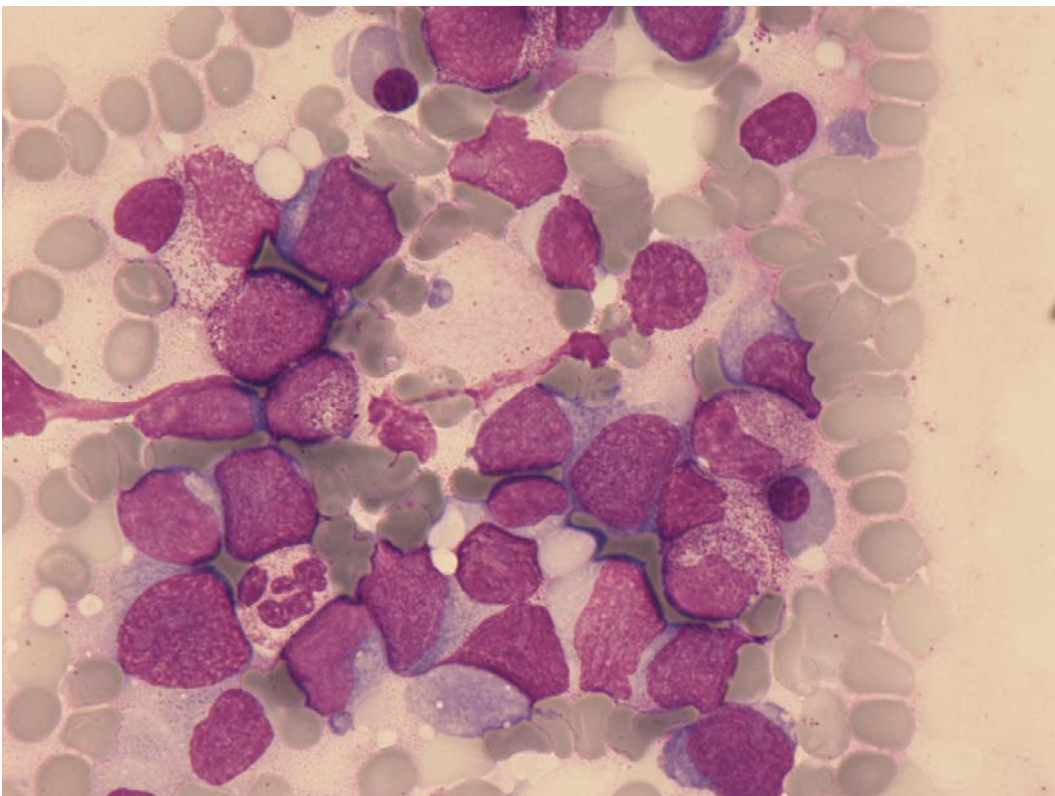


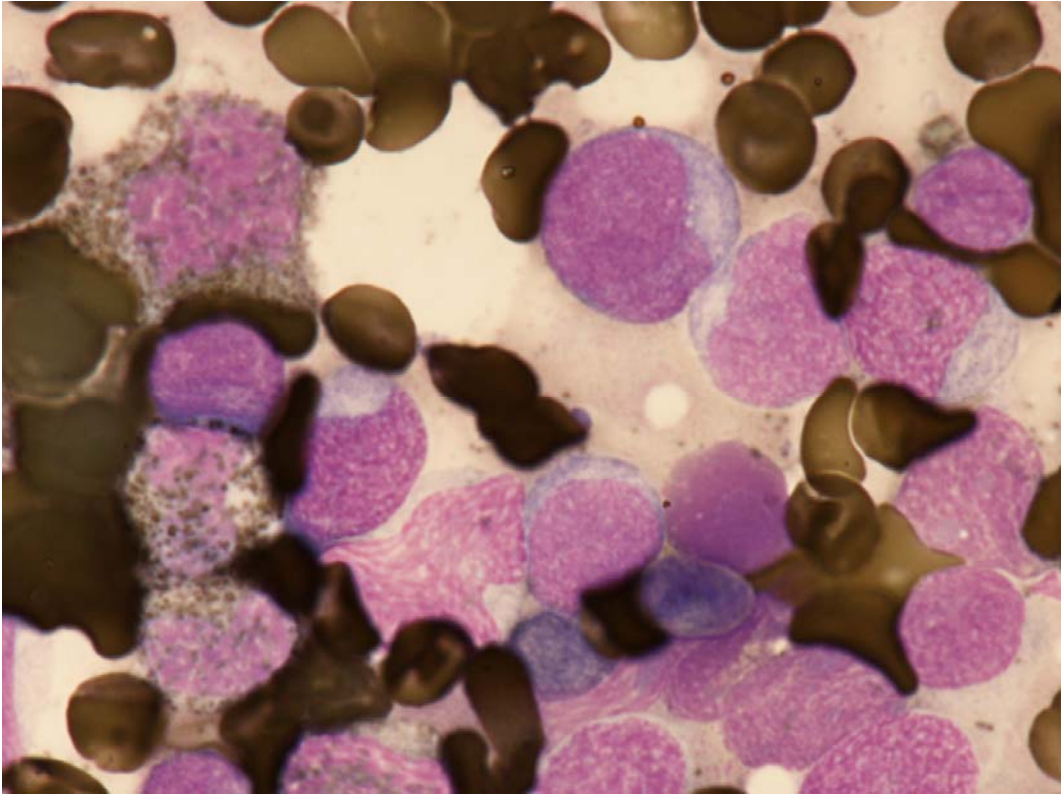
## Myeloid proliferations related to Down syndrome



**Fig 1:** Blasts with round nuclei and a moderate amount of basophilic cytoplasm with scarce blebs.



**Fig 2:** Blasts with round nuclei and a moderate amount of basophilic cytoplasm and maturing cells of neutrophil and erythroid lineage.



**Fig 3:** Blasts MPO negative.