

Acute myeloid leukaemia with minimal differentiation

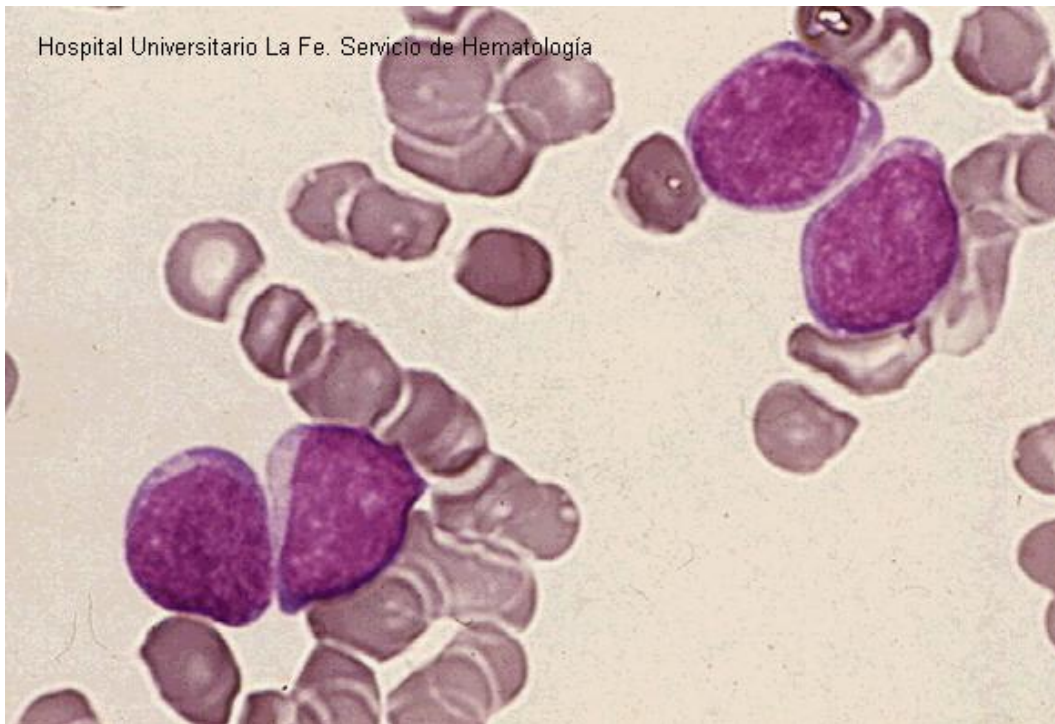


Fig 1: Blasts with round nuclei with one or two nucleoli and cytoplasm agranular.

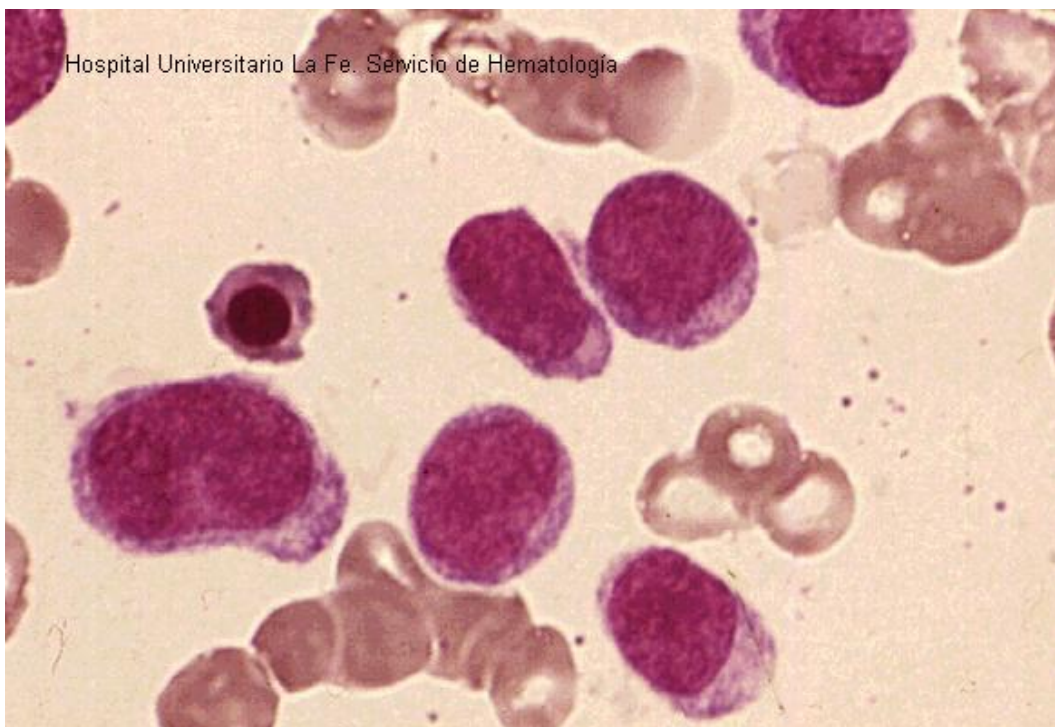


Fig 2: Blasts with round nuclei with no evidence of myeloid differentiation in bone marrow.

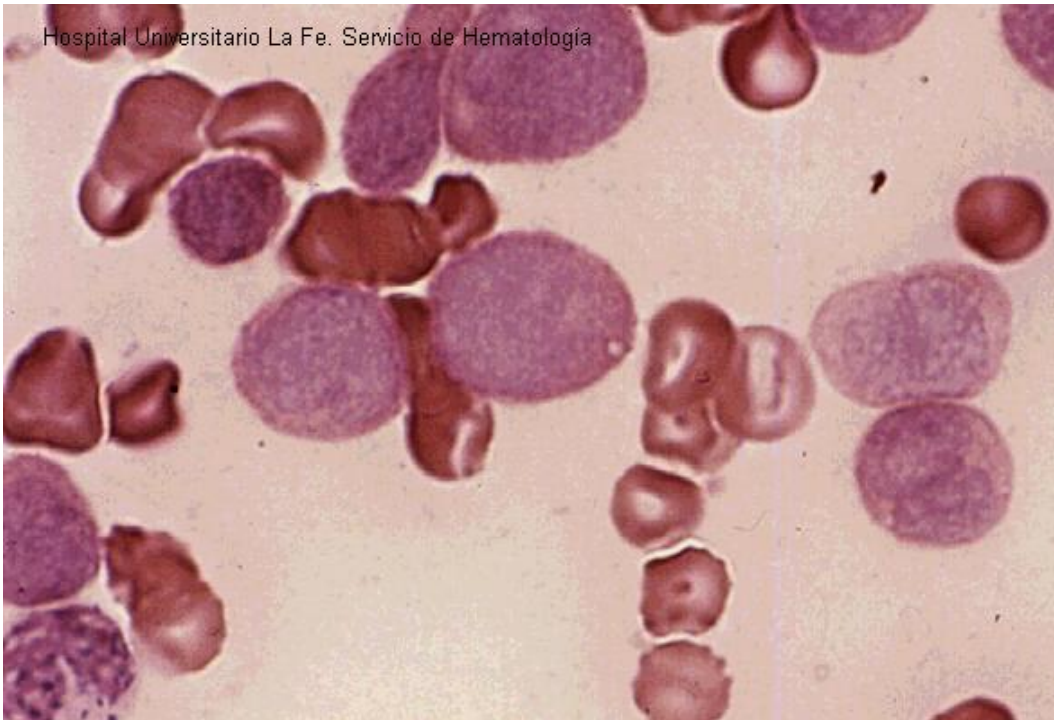


Fig 3: CAE negative.

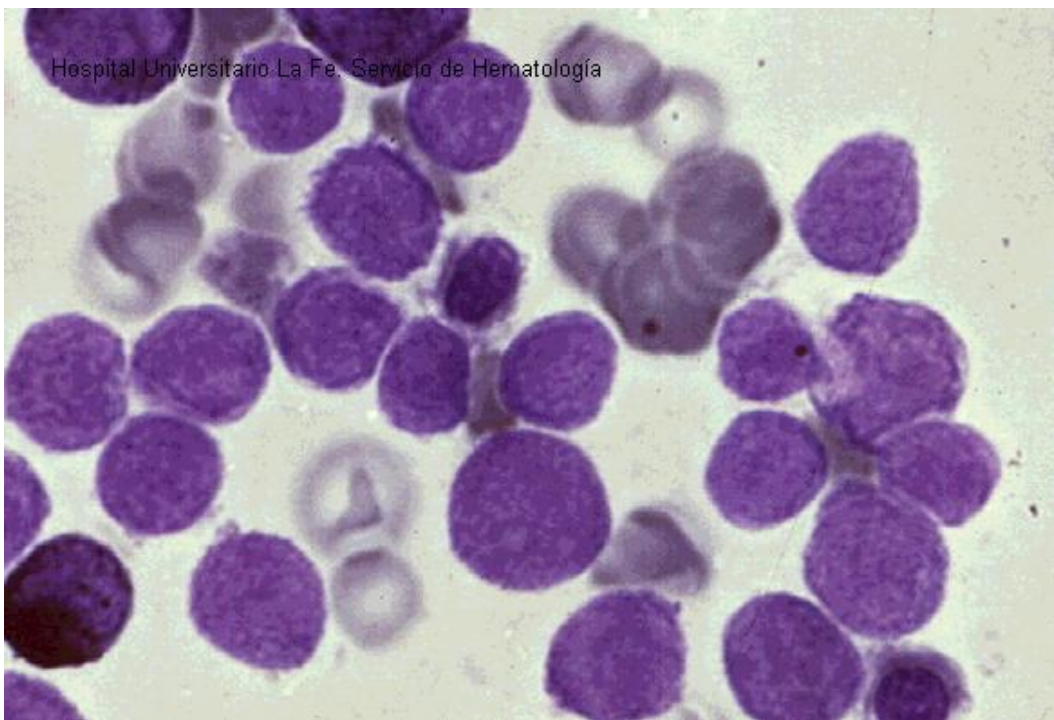


Fig 4: Sudan Black B negative.