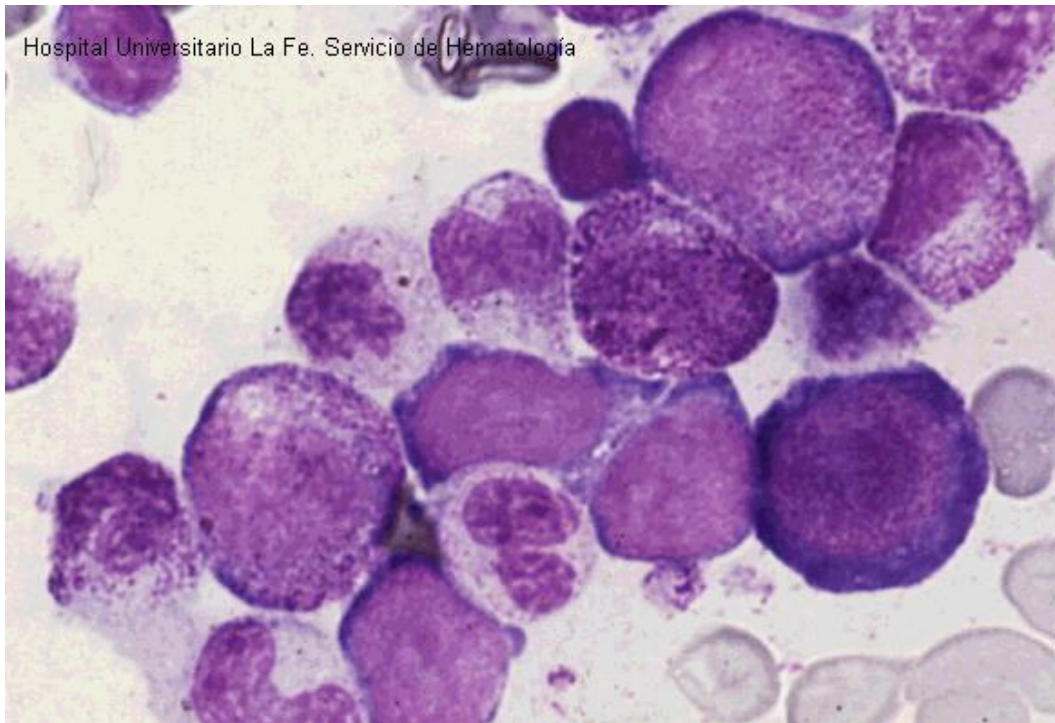
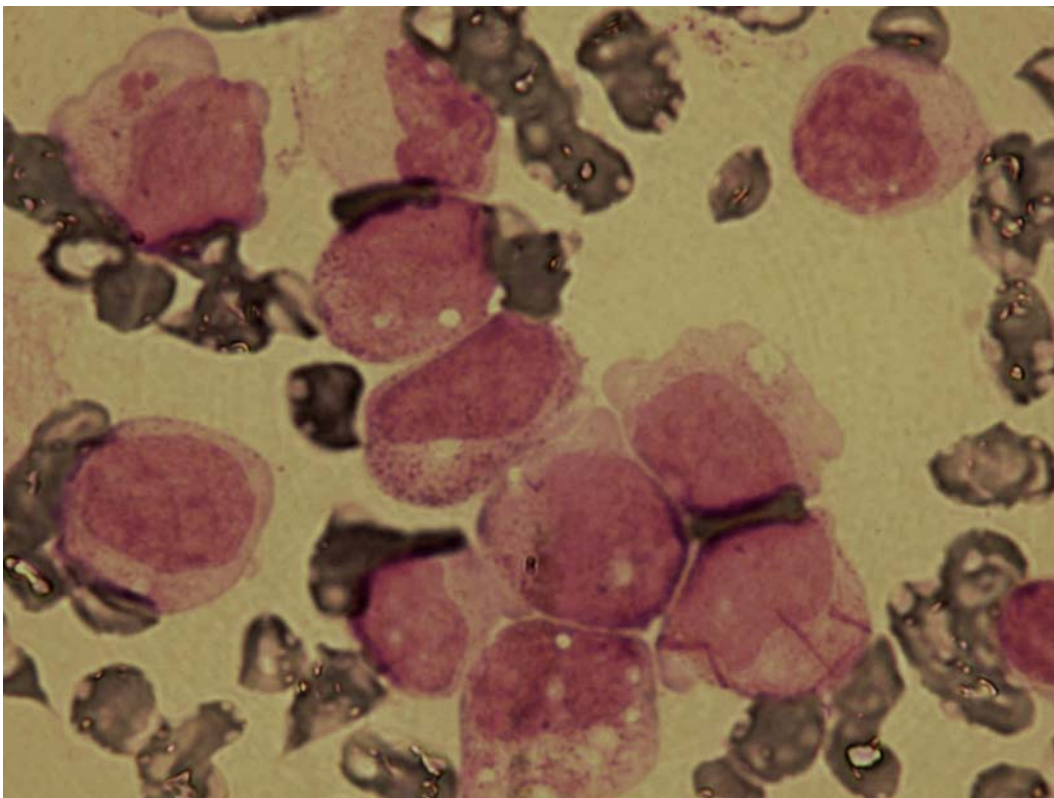


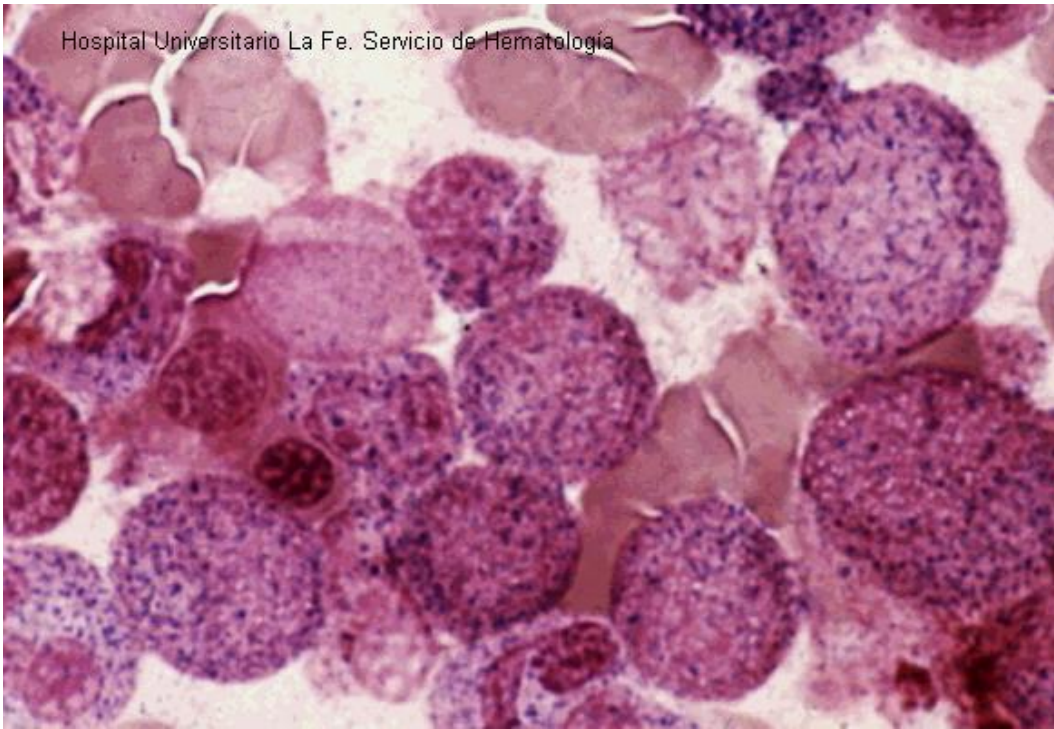
## Acute myeloid leukaemia with maturation



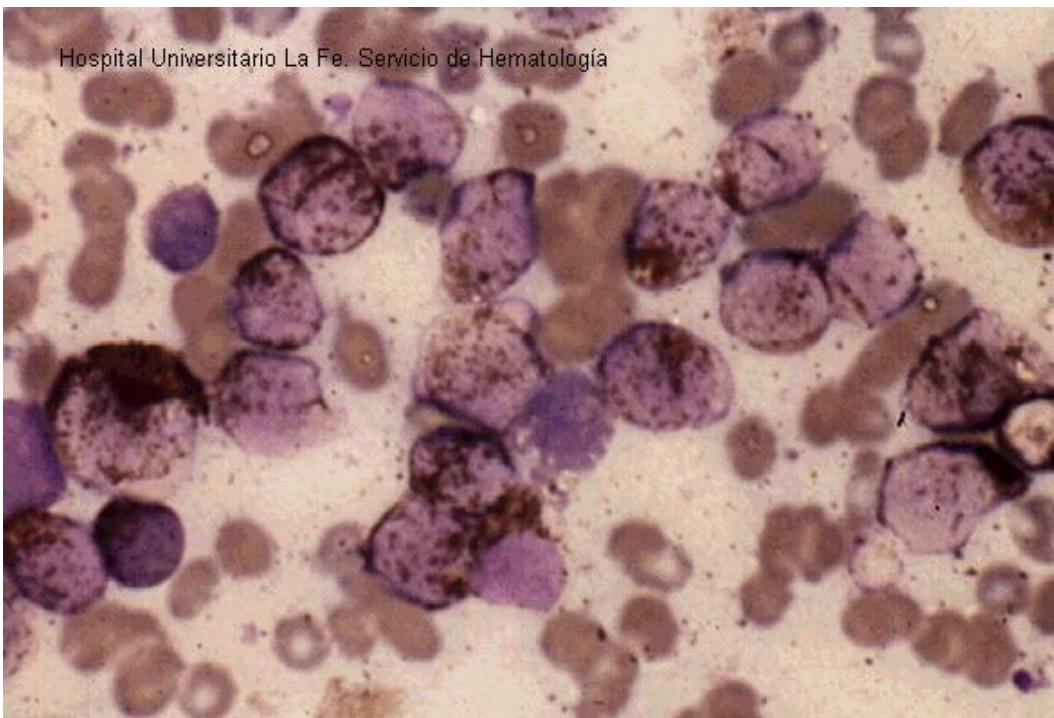
**Fig 1:** Blasts without azurophilic granulation and promyelocytes, myelocytes and mature neutrophils (bone marrow).



**Fig 2:** Blasts with scarce azurophilic granulation and neutrophils with dysplastic features. A blast with several Auer rods (bone marrow).

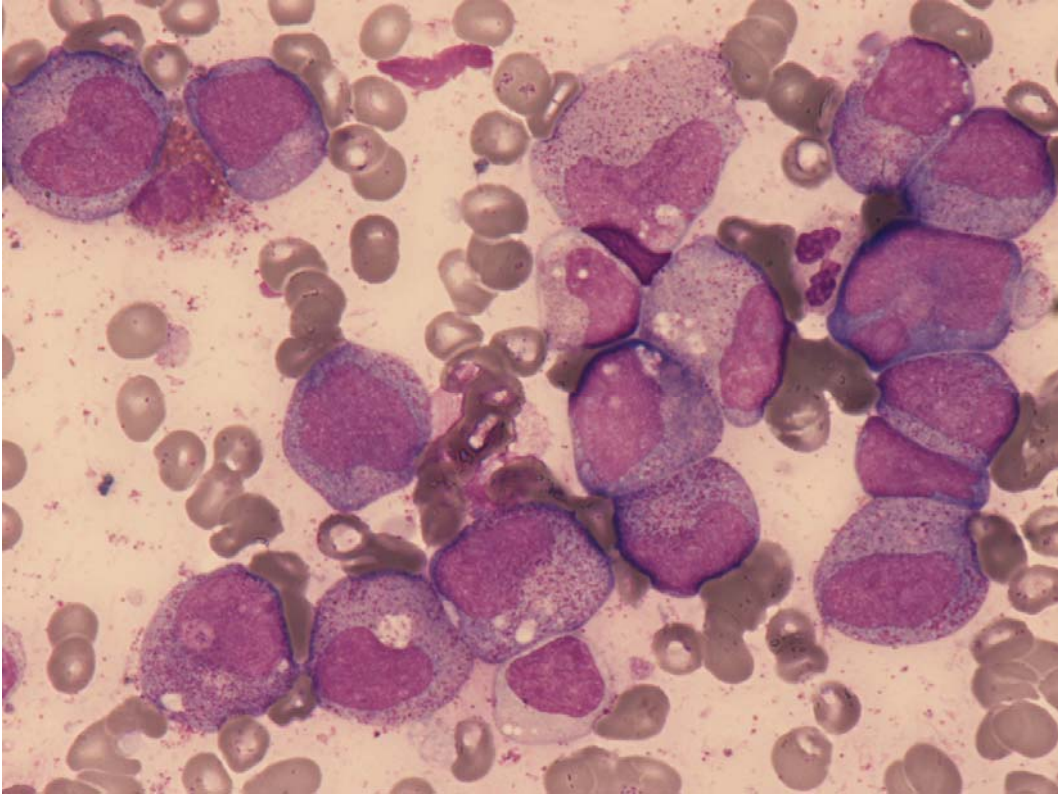


**Fig 3:** Blasts CAE positive (bone marrow). (cloracetato esterasa pos).

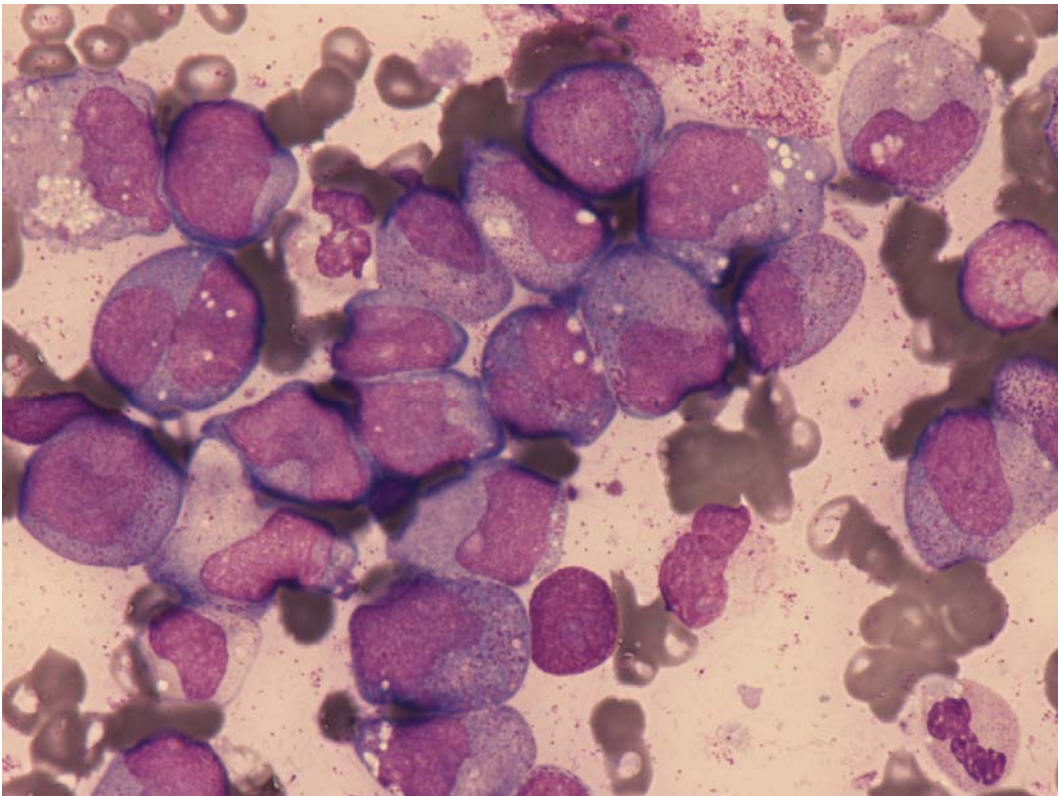


**Fig 4:** Blasts MPO positive (bone marrow).





**Fig 5:** Blasts MPO positive (bone marrow).



**Fig 6:** Myeloid maturation (bone marrow).